DOPPLER HEPÁTICO

NORMAL E NA HIPERTENSÃO PORTAL

Túlio A. A. Macedo

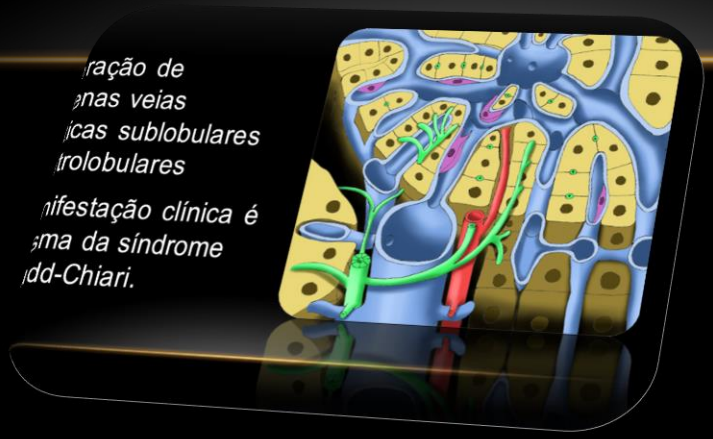

Universidade Federal de Uberlândia

DOPPLER NORMAL DA VEIA PORTA

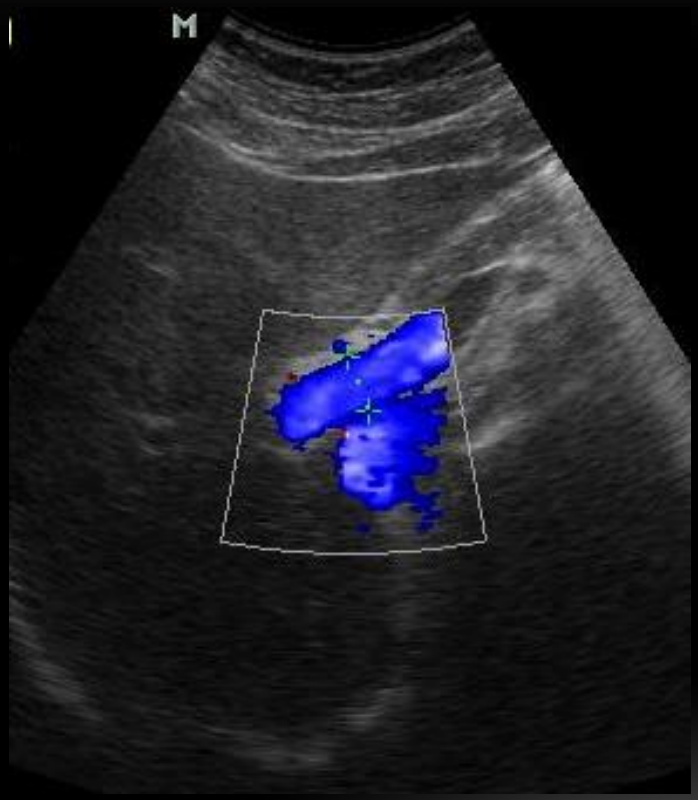

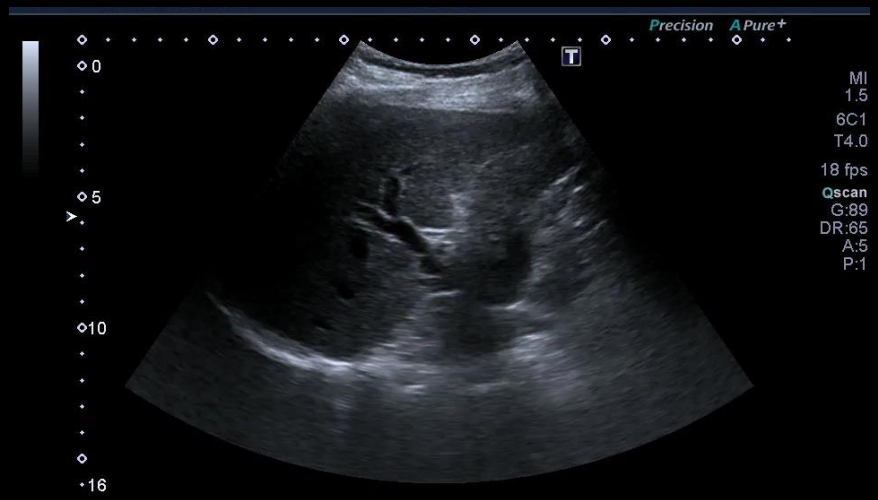

TÚLIO MACEDO - TAMACEDO@HOTMAIL.COM

DOPPLER NORMAL DA ARTÉRIA HEPÁTICA

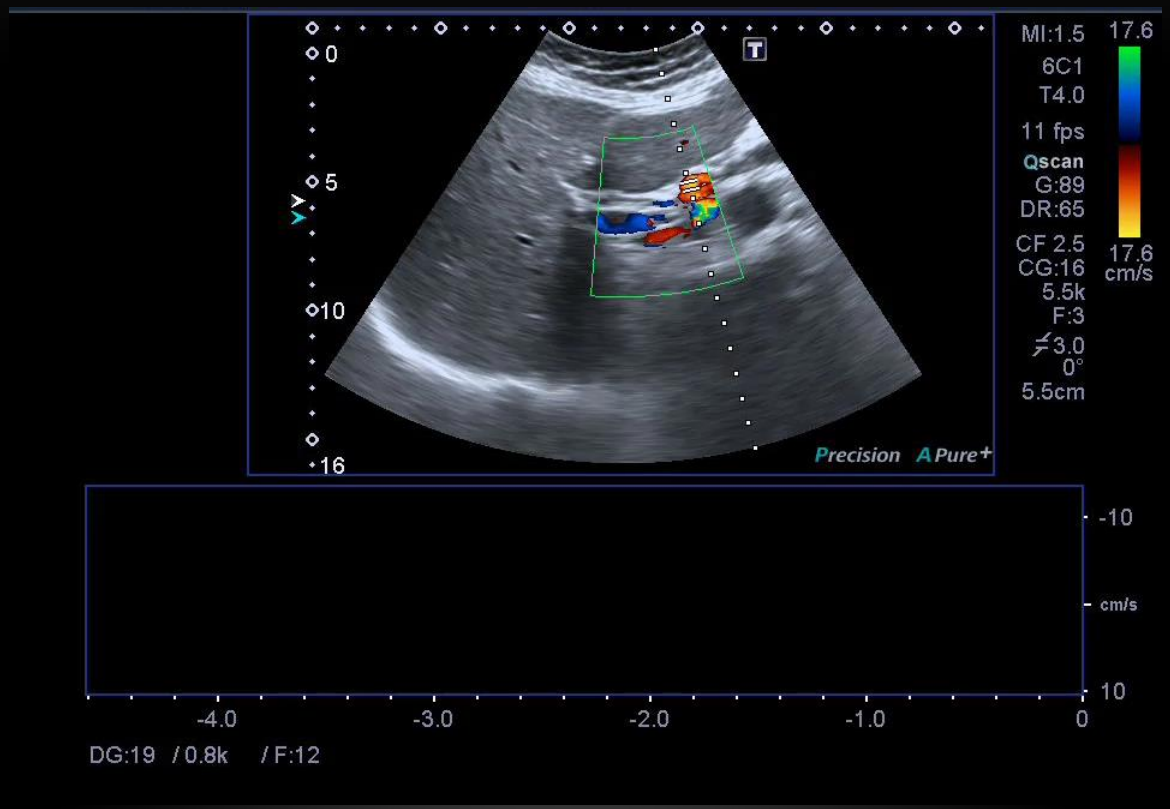

TÚLIO MACEDO - TAMACEDO@HOTMAIL.COM

DOPPLER NORMAL DAS VEIAS HEPÁTICAS

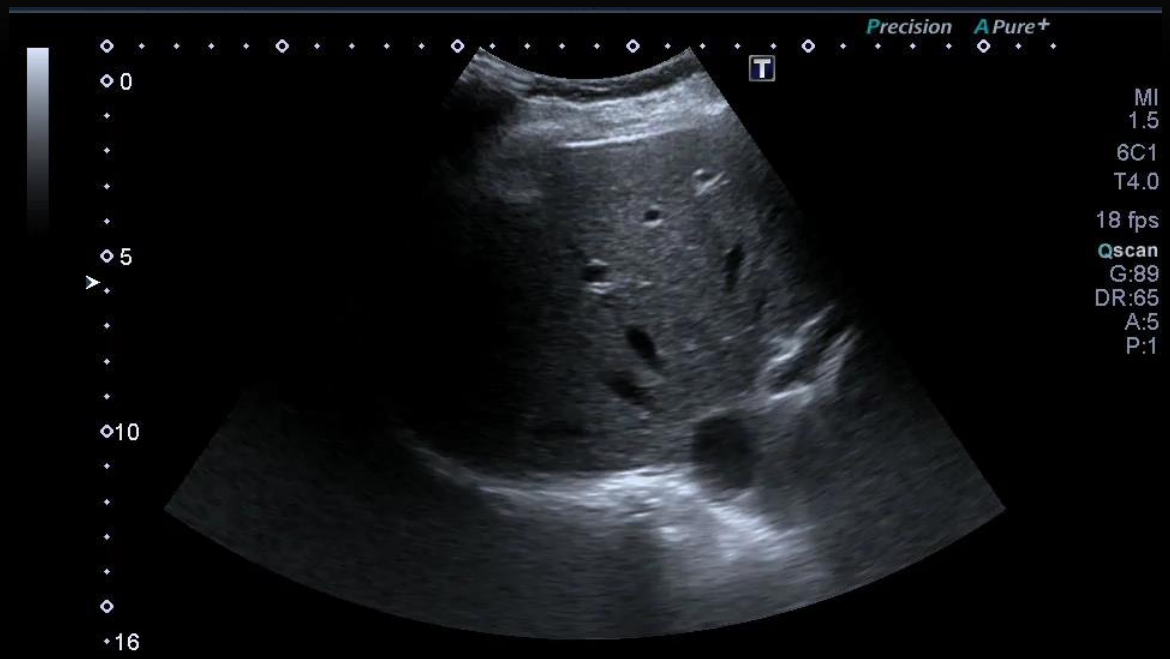

TÚLIO MACEDO - TAMACEDO@HOTMAIL.COM

HIPERTENSÃO PORTAL

- Aumento da pressão no sistema portal hepático (≥ 12 mmHg)
  - Tipos
    - Pré-sinusoidal
      - Trombose da veia porta
      - Esquistosomose
    - Sinusoidal
      - Cirrosis
    - Pós-sinusoidal
      - Budd-Chiari
      - D. veno-oclusiva, ICC

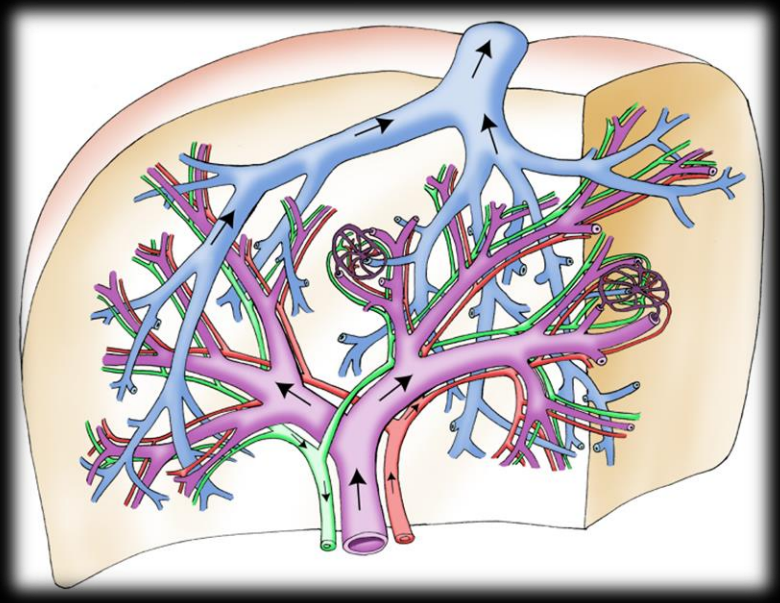

SINAIS DOPPLER DE HIPERTENSÃO PORTAL

- Veia porta
  - VP dilatada
  - Diminuição da velocidade média (<15 cm/s)
  - Fluxo "vai e vem"/ hepatofugal
  - Aumento da pulsatilidade (VPI)
  - Fístula arterio-portal
- Veia hepática
  - Fluxo pseudoportal
- Arteria hepática
  - Ampliação e tortuosidade
  - Aumento de IR e IP
- Colaterais portossistêmicas

Harkanyi Z. Ultrasound Clin 2006 ; 1 : 443 – 455.

DIÂMETRO DA VEIA PORTA

Contovérsia no diâmetro normal da VP

Até 12 mm[1]
Até 16 mm[2]

Tamanho normal da VP: não exclui HPP

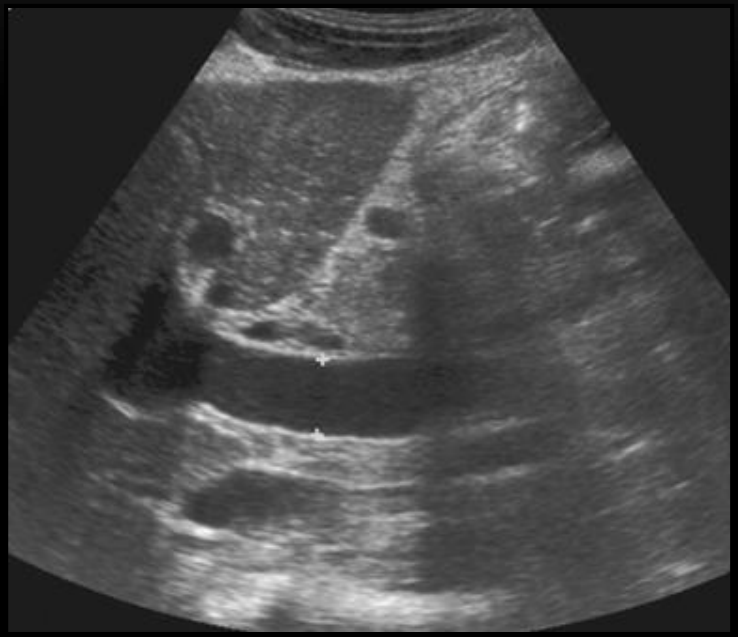

Diâmetro: 17 mm
Sinal de hipertensão portal

[1] Chammas et al. Ultrassonografia abdominal, 2009.
[2] Goyal AK et al. J Ultrasound Med 1990 ; 9 : 45 – 48.
Robinson KA et al. Ultrasound Quarterly 2009 ; 25 : 3 – 13.

HIPERTENSÃO PORTAL

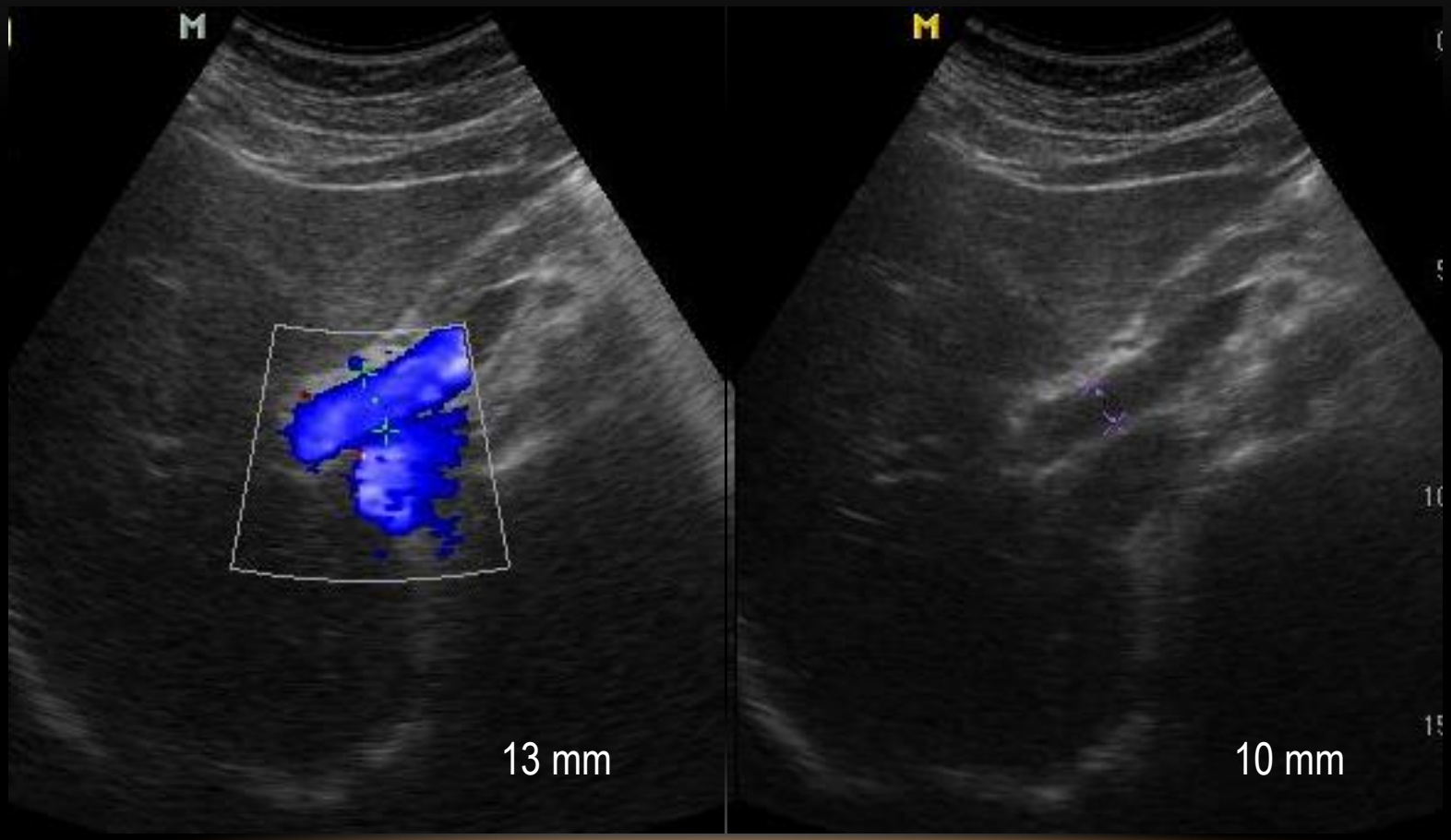

TÚLIO MACEDO - TAMACEDO@HOTMAIL.COM

HIPERTENSÃO PORTAL

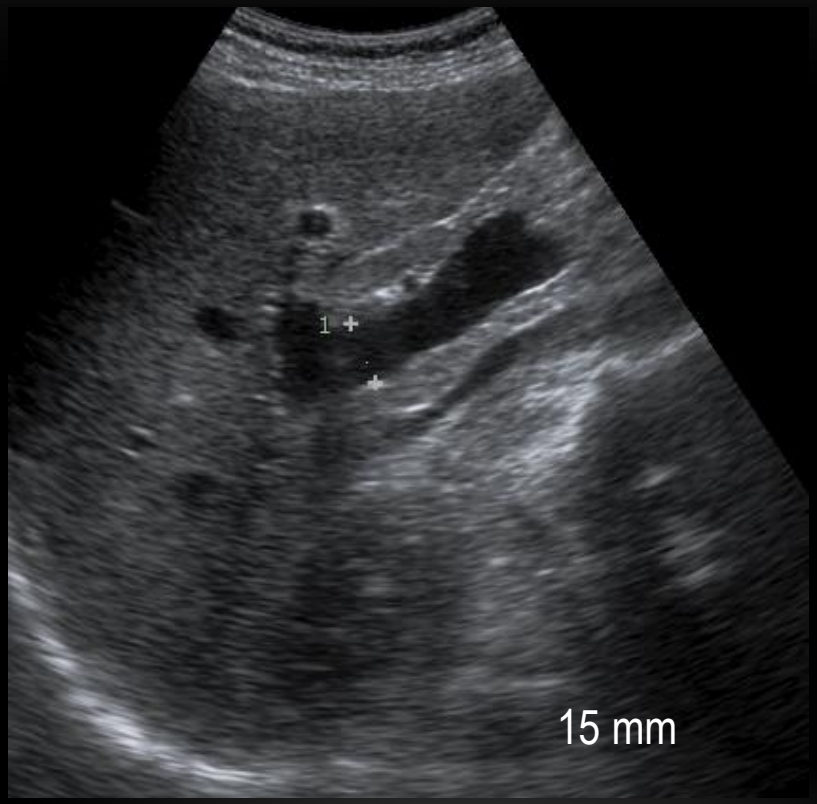

TÚLIO MACEDO - TAMACEDO@HOTMAIL.COM

VELOCIDADE DA VEIA PORTA

Controvérsia sobre a velocidade da VP

Reprodutibilidade prejudicada
Velocidade média normal: 15 a 18 cm / seg

Velocidade baixa: bom indicador da hipertensão portal

Velocidade normal: não exclui a HP

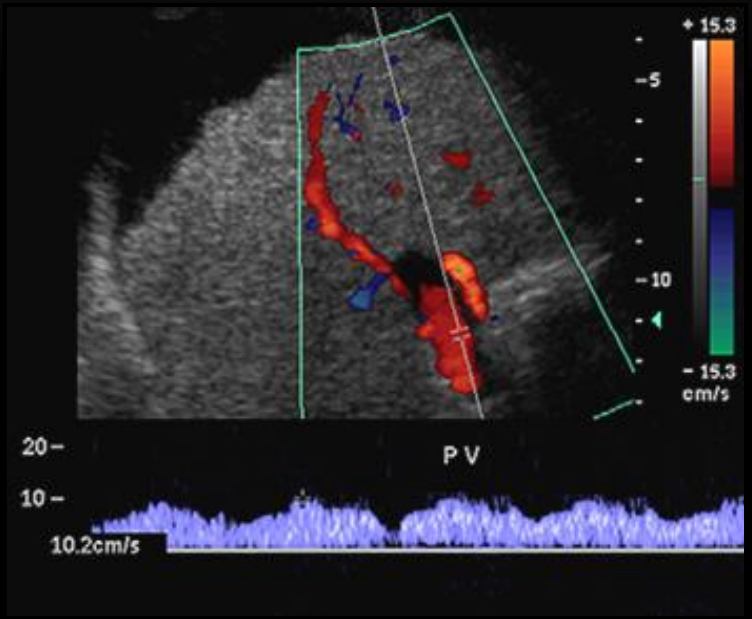

Fígado reduzida e contornos lobulados
Vmed: 10 cm / seg

Swart J et al. Ultrasound Clin 2007 ; 2 : 355 – 375.

HIPERTENSÃO PORTAL E O FLUXO DA VEIA PORTA

Fluxo normal

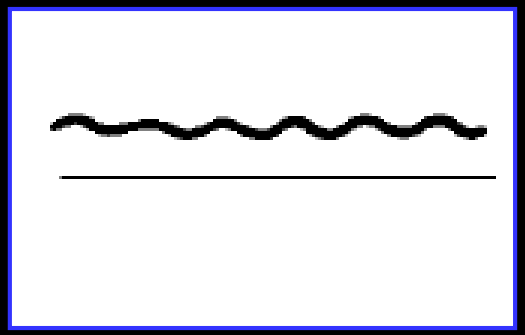

Fluxo "To and fro"

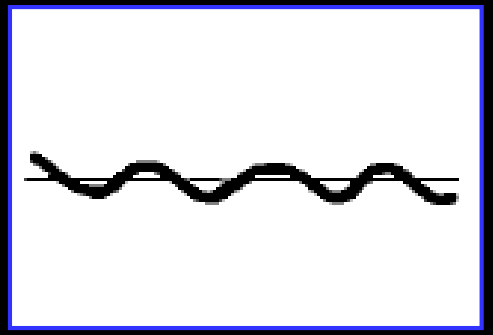

Hipertensão portal avançada

Insuficiência cardíaca

Fístula arterio-portal

Fluxo invertido

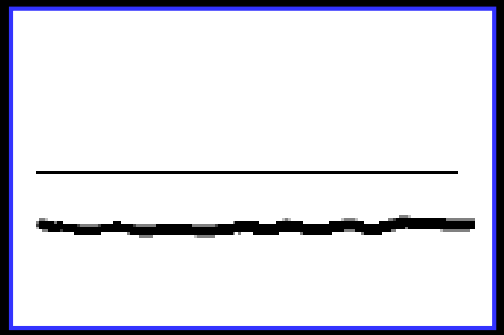

HP avançada

Shunt porto-sistêmico

Kok Th et al. Scand J Gastroenterol 1999 ; 34 (Suppl 230) : 82 – 88.

“TO-AND-FRO FLOW” - FLUXO TIPO "VAI E VEM"

Estudo Doppler realizado em apneia

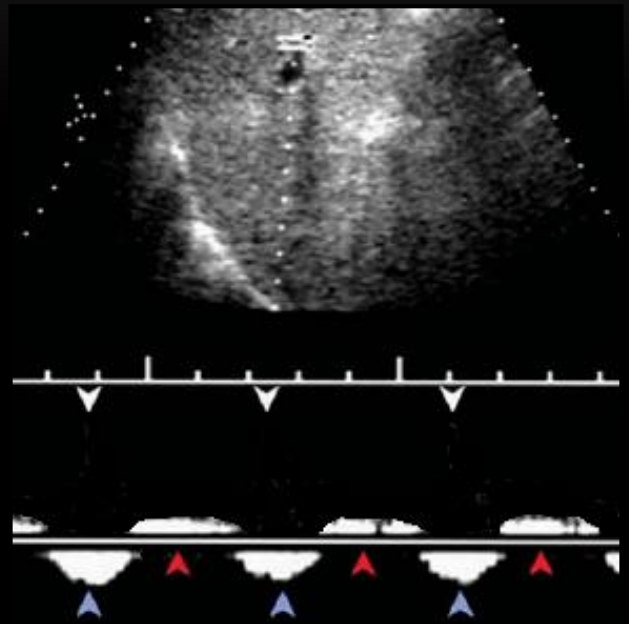

Fluxo hepatopetal e hepatofugal a cada batimento cardíaco

Estágio prévio ao fluxo hepatofugal

Wachsberg RH et al. RadioGraphics 2002 ; 22 : 123 – 140.

CAUSAS DO FLUXO "VAI E VEM"

- Hipertensão portal
- Insuficiência tricúspide
- Insuficiência cardíaca direita
- Fístula venosa arterioportal

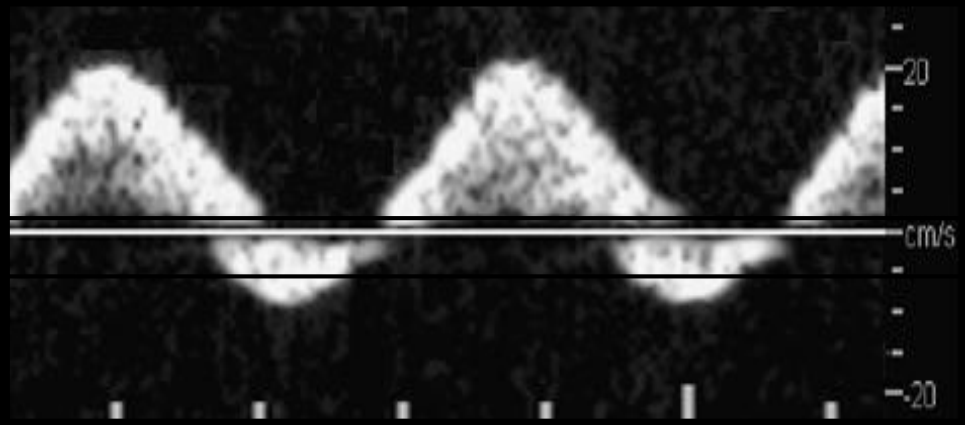

Robinson KA et al. Ultrasound Quarterly 2009 ; 25 : 3 – 13.

FLUXO HEPATOFUGAL

Hipertensão portal grave - raro

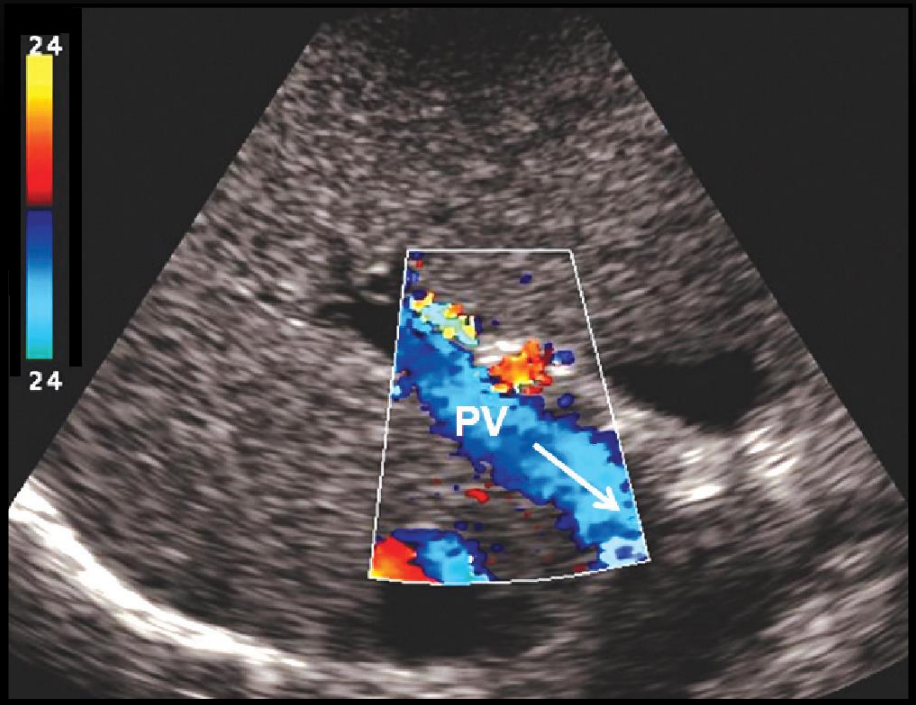

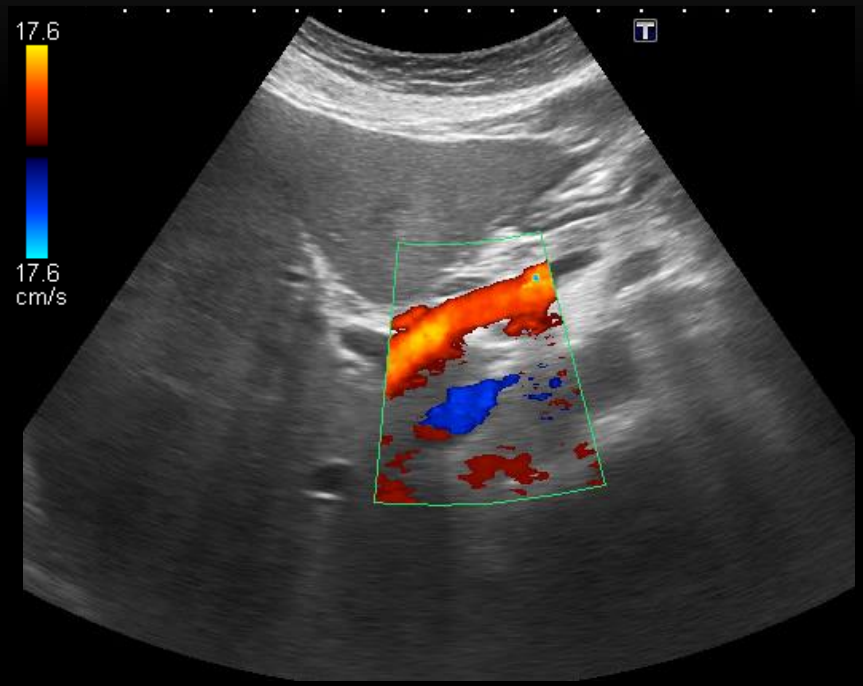

Não é patognomônico de cirrose

Robinson KA et al. Ultrasound Quarterly 2009 ; 25 : 3 – 13.

PSEUDOCOÁGULO DA VEIA PORTA

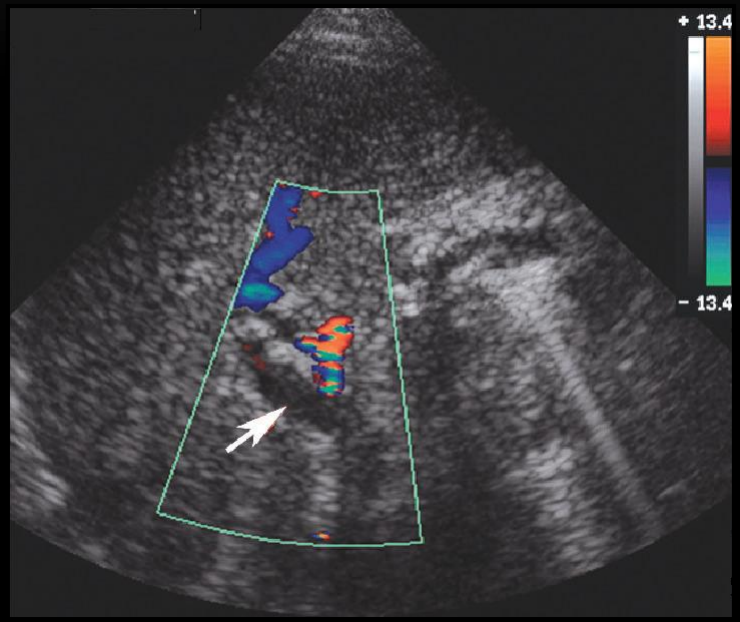

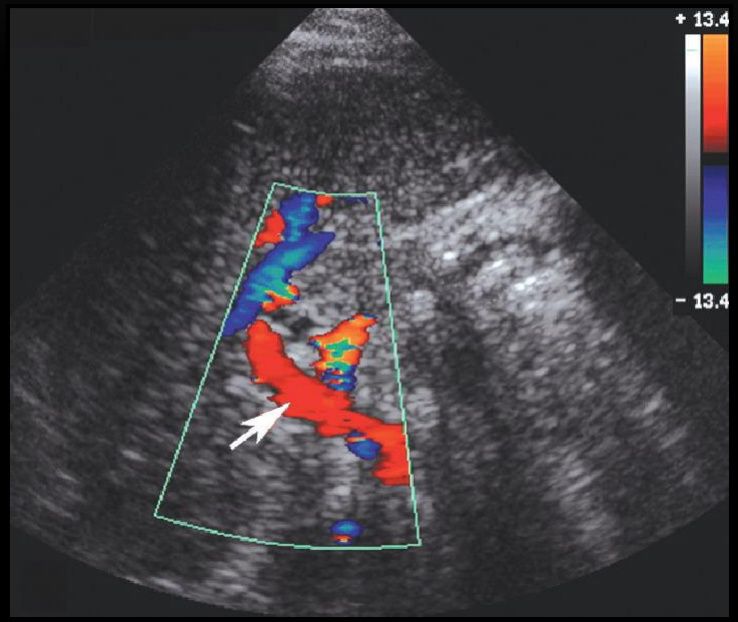

Depois da compressão da parte inferior do abdome

SINAIS DOPPLER DE HIPERTENSÃO PORTAL

- Veia porta
  - VP dilatada
  - Diminuição da velocidade média (<15 cm/s)
  - Fluxo "vai e vem"/ hepatofugal
  - Aumento da pulsatilidade (VPI)
  - Fístula arterio-portal
- Veia hepática
  - Fluxo pseudoportal
- Arteria hepática
  - Ampliação e tortuosidade
  - Aumento de IR e IP
- Colaterais portossistêmicas

Harkanyi Z. Ultrasound Clin 2006 ; 1 : 443 – 455.

OS DIFERENTES TIPOS DE FLUXO NA VEIA HEPÁTICA

Multifásico

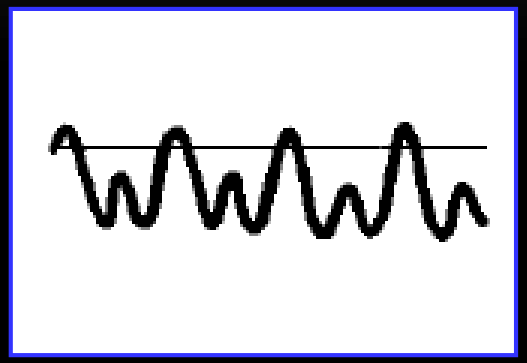

Bifásico

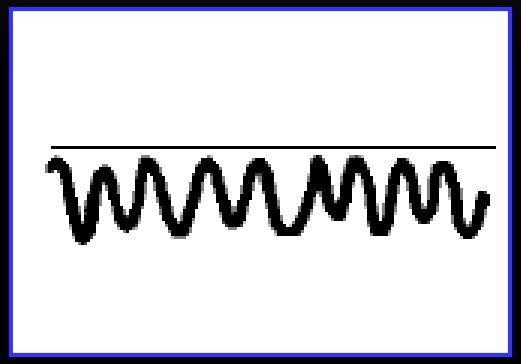

Cirrose
Síndrome Budd-Chiari
Metástases
Ascite

Monofásico

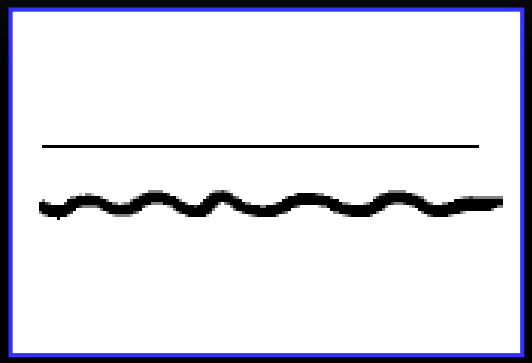

Cirrosis
Síndrome Budd-Chiari
Metástases
Ascite

Kok Th et al. Scand J Gastroenterol 1999 ; 34 (Suppl 230) : 82 – 88.

DAMPING INDEX

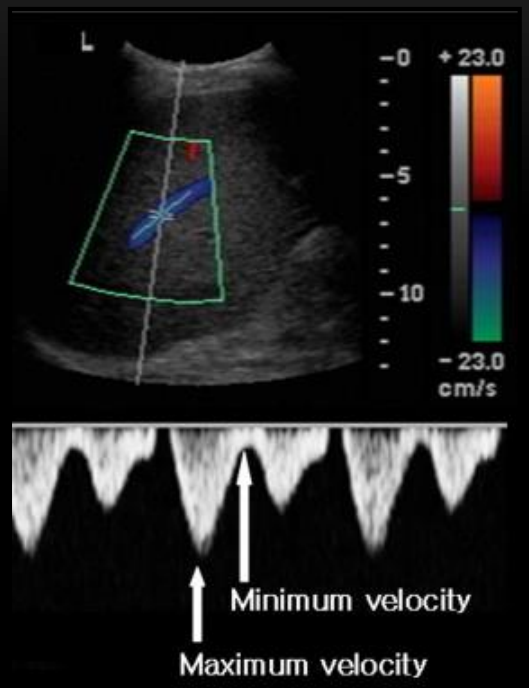

DI: 0.26
HVPG: 7 mmHg

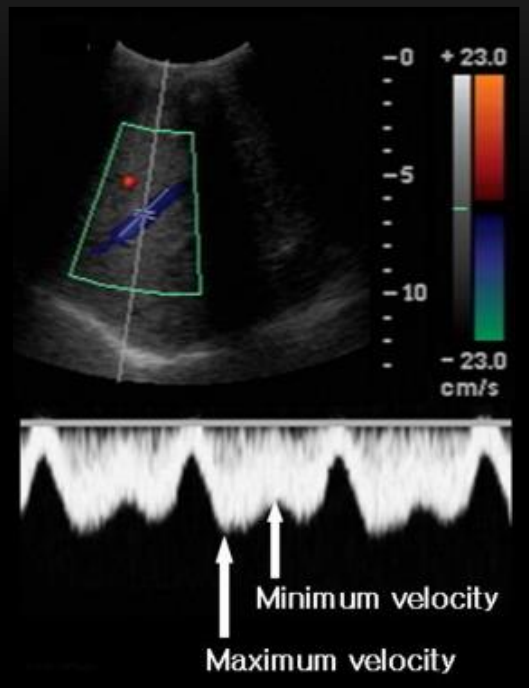

DI: 0.72
HVPG: 15 mmHg

Sens. 76%
Spec. 82%

Kim MY et al. Liver International 2007 ; 27 : 1103 – 1110.

ÍNDICE DE “PORTALIZAÇÃO” DA VEIA HEPÁTICA (DAMPING INDEX)

Damping index

Valor normal: < 0,6

Hipertensão portal grave: ≥ 0,6

Kim MY et al. Liver International 2007 ; 27 : 1103 – 1110.

FLUXO CONTÍNUO DA VEIA HEPÁTICA MEDIA (PSEUDOPORTAL)

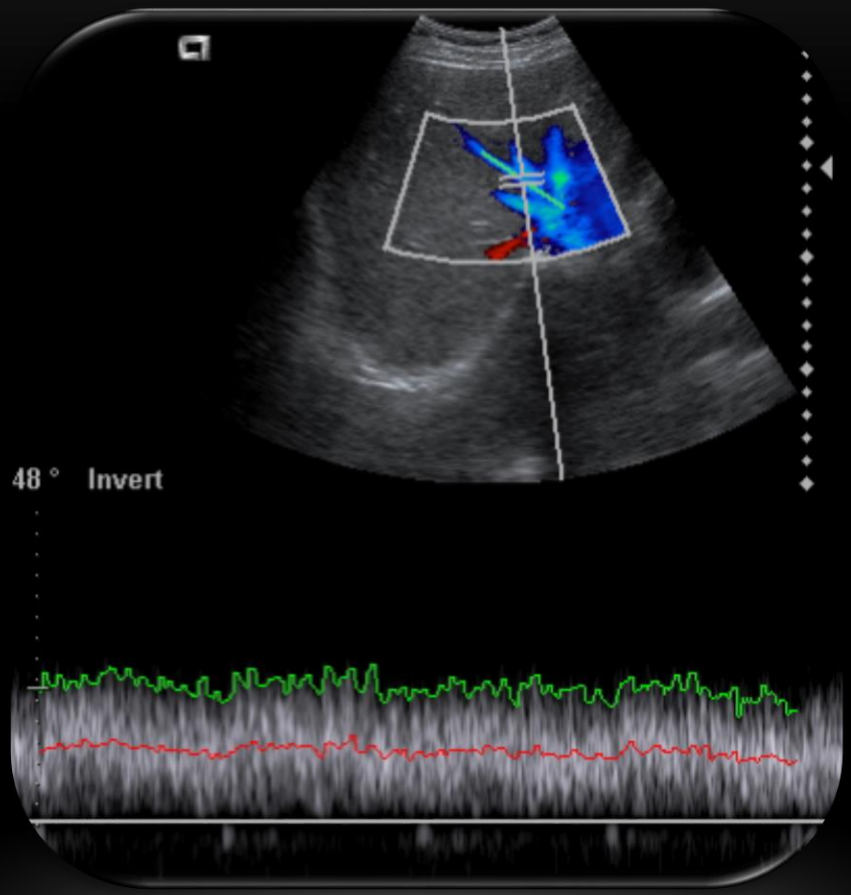

TÚLIO MACEDO - TAMACEDO@HOTMAIL.COM

SINAIS DOPPLER DE HIPERTENSÃO PORTAL

- Veia porta
  - VP dilatada
  - Diminuição da velocidade média (<15 cm/s)
  - Fluxo "vai e vem"/ hepatofugal
  - Aumento da pulsatilidade (VPI)
  - Fístula arterio-portal
- Veia hepática
  - Fluxo pseudoportal
- Arteria hepática
  - Ampliação e tortuosidade
  - Aumento de IR e IP
- Colaterais portossistêmicas

Harkanyi Z. Ultrasound Clin 2006 ; 1 : 443 – 455.

ARTERIA HEPÁTICA PROEMINENTE

AH proeminente com aspecto tortuoso ou sacarrolhas
O aumento do fluxo da AH para compensar a diminuição de perfusão da VP

Swart J et al. Ultrasound Clin 2007 ; 2 : 355 – 375.

CAUSAS DE AUMENTO DA ARTÉRIA HEPÁTICA

Cirrose

Fibrose hepática congênita

Tumores vasculares

Telangiectasia hemorrágica hereditaria

Buscarini E et al. Ultraschall Med 2004 ; 25 : 348 – 55.

SINAL DO DUCTO PARALELO

Modo-B

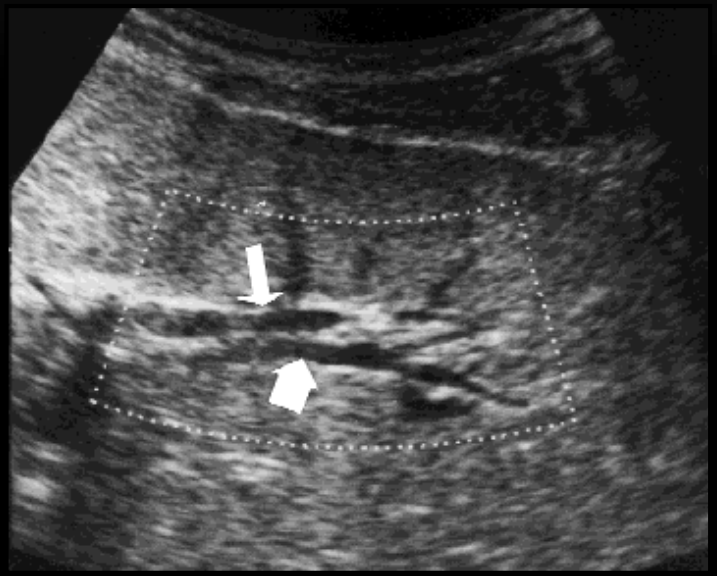

Doppler

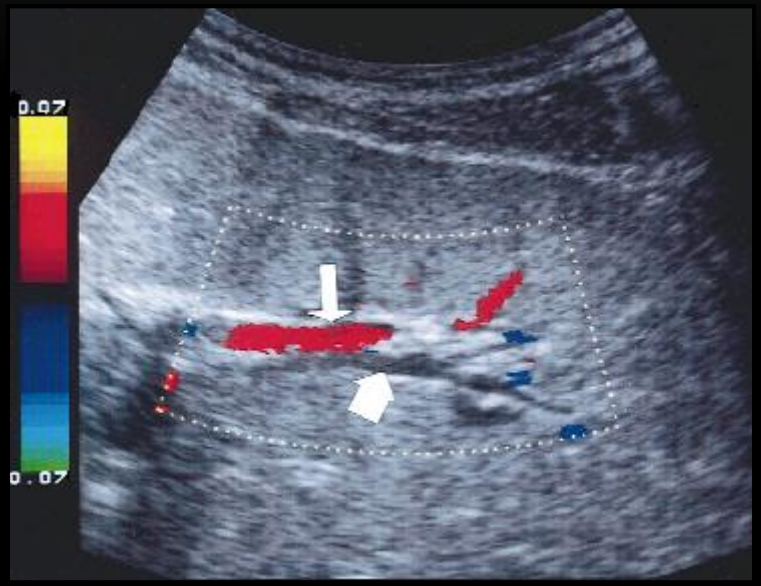

von Herbay A et al. J Clin Ultrasound 1999 ; 27 : 426 – 432.

AS VARIAÇÕES DE FLUXO DA ARTÉRIA HEPÁTICA

Fluxo normal



Diminuição de fluxo diastólico

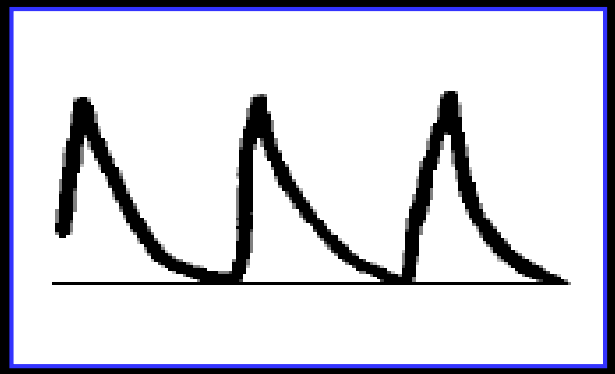

Fluxo diastólico invertido

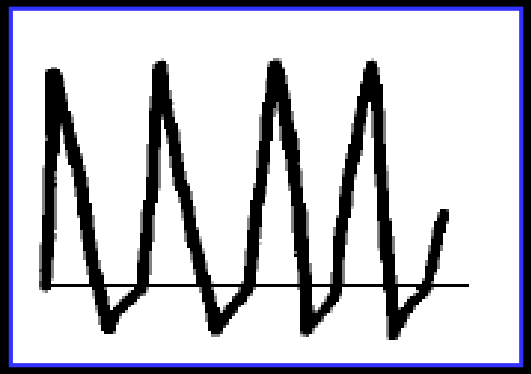

Kok Th et al. Scand J Gastroenterol 1999 ; 34 (Suppl 230) : 82 – 88.

ÍNDICE DE PULSATILIDADE (PULSATILITY INDEX)

CONTROLE X PACIENTES CIRRÓTICOS

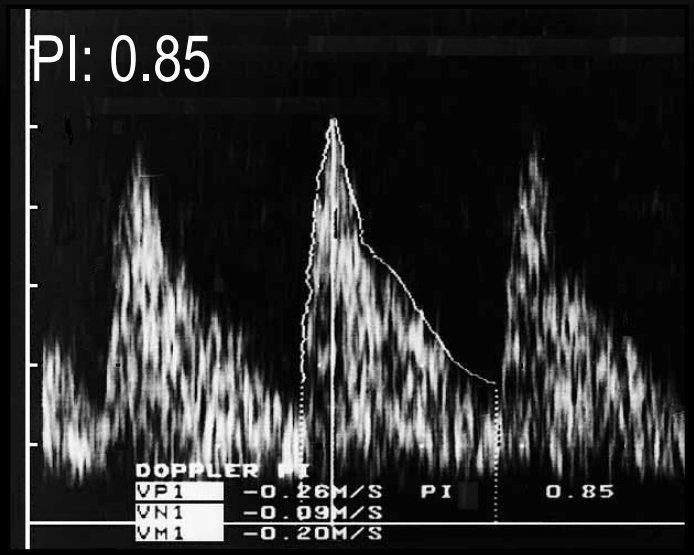

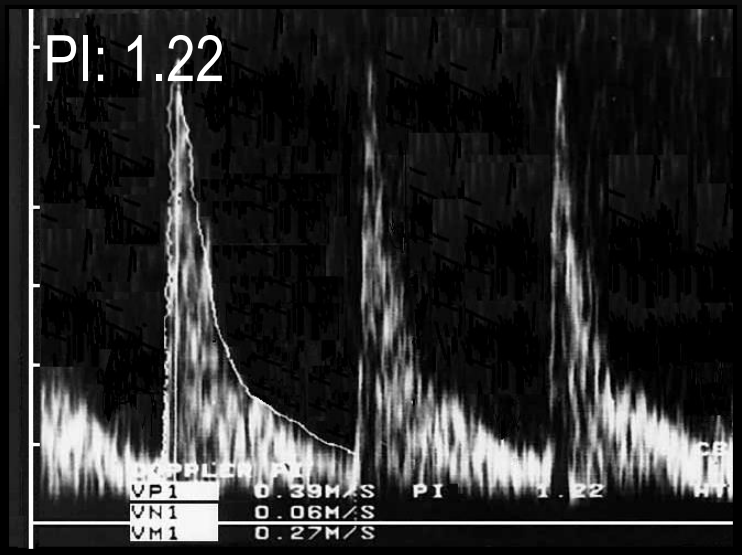

20 controles
0.92 ± 0.1

50 patientes cirróticos
1.14 ± 0.18

P< 0.001
Diretamente correlacionado com a hipertensão portal

Schneider AW et al. J Hepatol 1999 ; 30 : 876 – 881.

SINAIS DOPPLER DE HIPERTENSÃO PORTAL

- Veia porta
  - VP dilatada
  - Diminuição da velocidade média (<15 cm/s)
  - Fluxo "vai e vem"/ hepatofugal
  - Aumento da pulsatilidade (VPI)
  - Fístula arterio-portal
- Veia hepática
  - Fluxo pseudoportal
- Arteria hepática
  - Ampliação e tortuosidade
  - Aumento de IR e IP
- Colaterais portossistêmicas

Harkanyi Z. Ultrasound Clin 2006 ; 1 : 443 – 455.

COLATERAIS PORTO-SISTÊMICAS

ALTA SENSIBILIDADE E ESPECIFICIDADE

- Coleterais anatômicas

Já existentes

Veia coronária (gástrica esquerda)
Veias gástricas curtas
Ramos da VMS e VMI

- Colaterais neoformadas

“Novas formações ou recanalizadas"

-

Veia umbilical recanalizada
Colaterais esplenorrenais
Colaterais gastrorrenais
Colaterais retroperitoneais

Cabeça de medusa – recanalização da veia umbilical

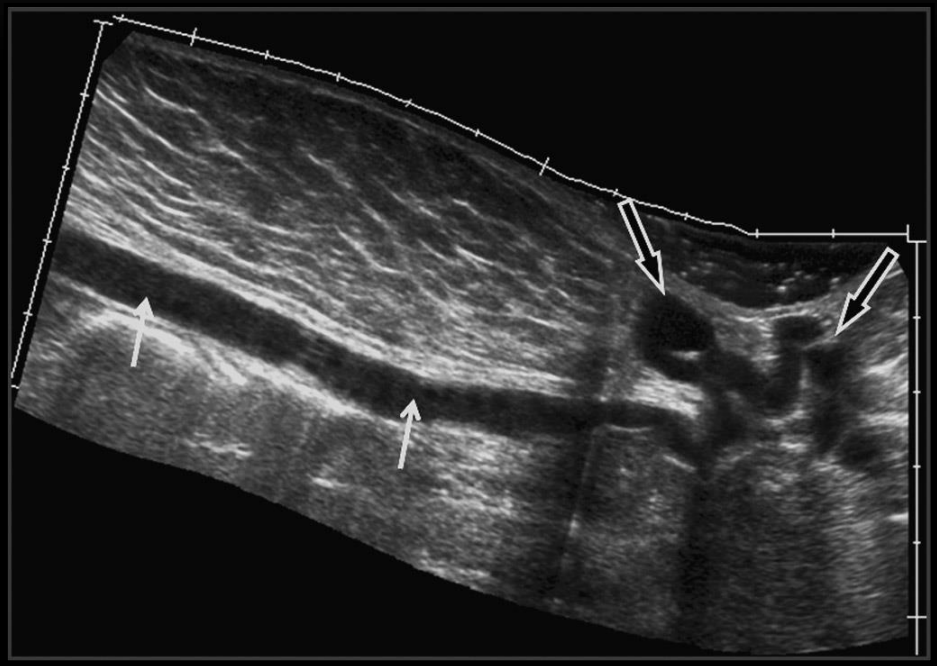

Robinson KA et al. Ultrasound Quarterly 2009 ; 25 : 3 – 13.
N Engl J Med 2005 ; 353 : e19.

HIPERTENSÃO PORTAL

VASOS COLATERAIS

Veia paraumbilical

TÚLIO MACEDO - TAMACEDO@HOTMAIL.COM

ANASTOMOSE ESPLENORRENAL

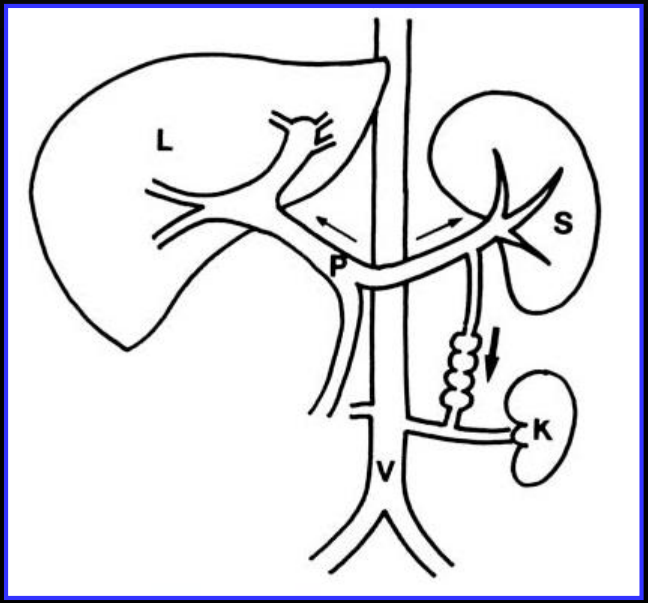

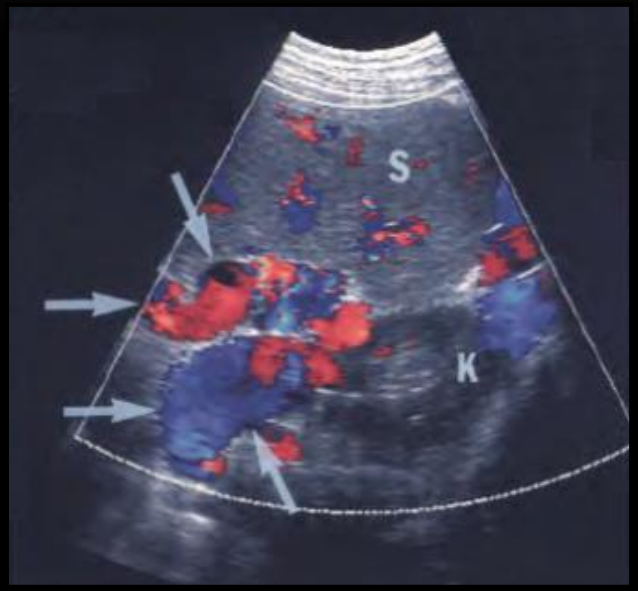

Yamada M et al. Abdom Imaging 2006 ; 31:701 – 705.
Mansour MA et al. Vascular Diagnosis. Elsevier-Saunders, Philadelphia, 1st edition, 2005.

ANASTOMOSE ESPLENORRENAL – FLUXO INVERSO NA VEIA ESPLÊNICA

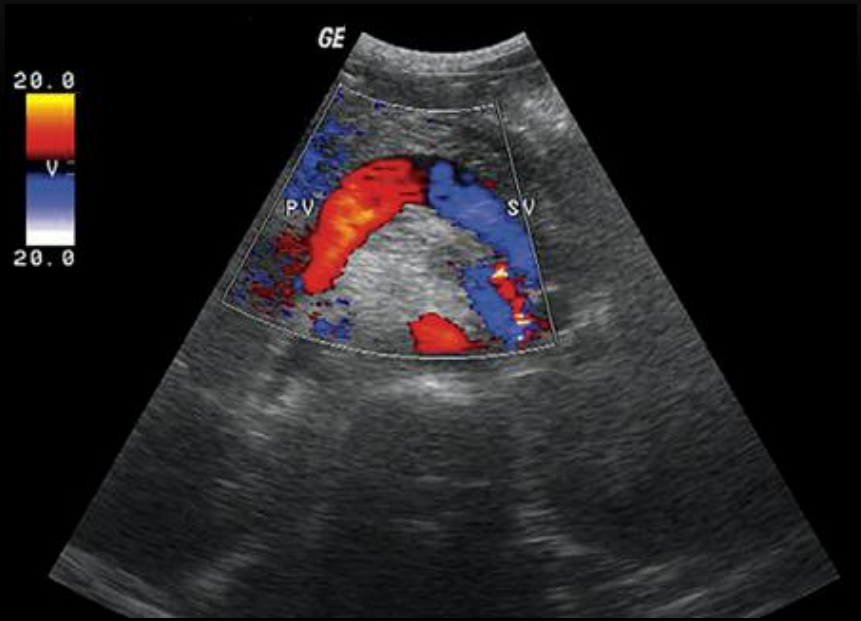

Mansour MA et al. Vascular Diagnosis. Elsevier-Saunders, Philadelphia, 1st edition, 2005

VEIAS GÁSTRICAS CURTAS

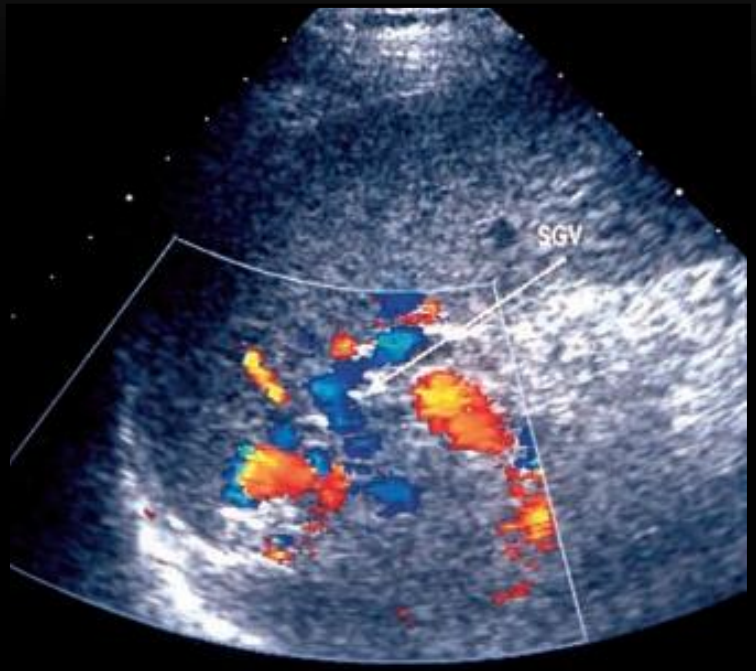

Sato T et al. J Gastroenterol 2002 ; 37 : 604 – 610.

GASTRORRENAL COLATERAL



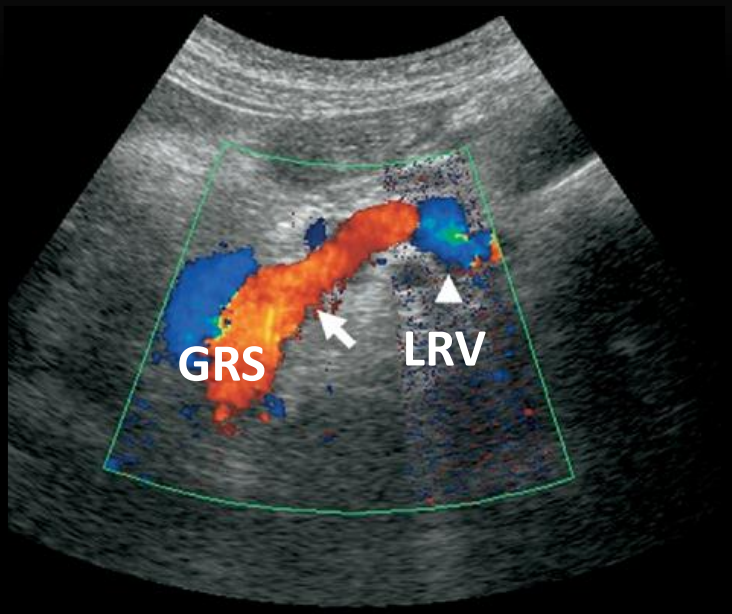

Yamada M et al. Abdom Imaging 2006 ; 31 : 701 – 705.
Maruyama H et al. Acad Radiol 2008 ; 15 : 1148 – 1154.

VASOS ESPLENOLOMBARES

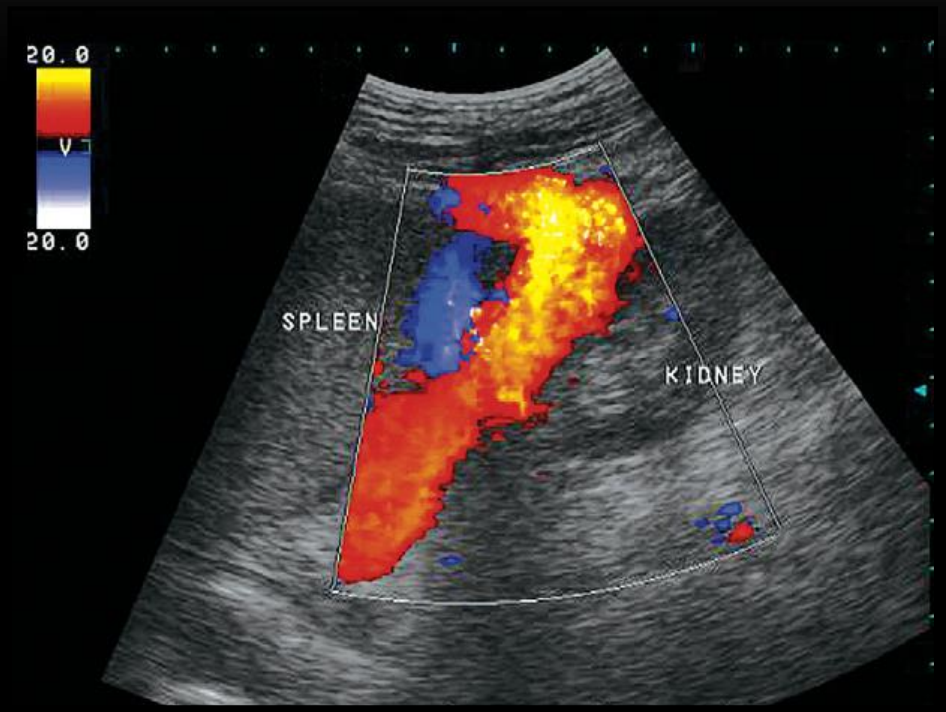

Mansour MA et al. Vascular Diagnosis. Elsevier-Saunders, Philadelphia, 1st edition, 2005

VEIA MESENTÉRICA INFERIOR – INVERSÃO DO FLUXO

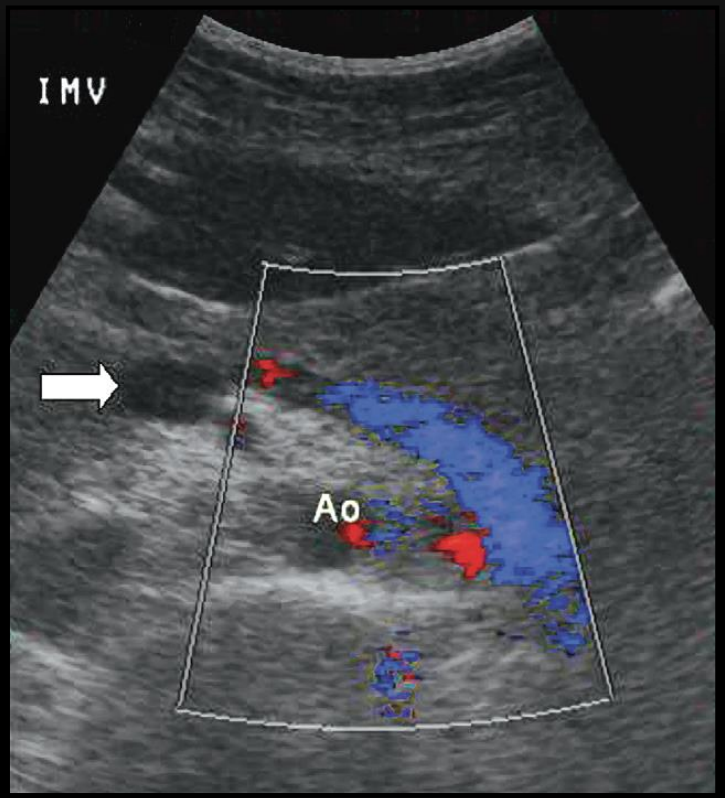

Mansour MA et al. Vascular Diagnosis. Elsevier-Saunders, Philadelphia, 1st edition, 2005.

VASOS COLATERAIS RETROPERITONEAIS

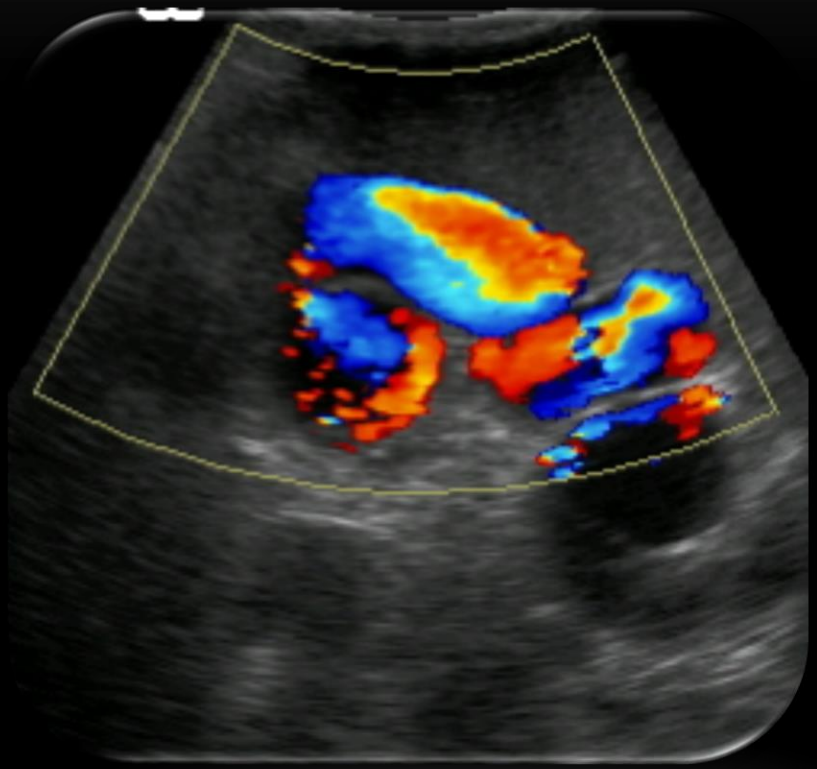

Wachsberg RH. Am J Roentgenol 2005 ; 184 : 481 – 486.

INVERSÃO DE FLUXO NA VEIA MESENTÉRICA INFERIOR E VARIZES PERIRRETAIS

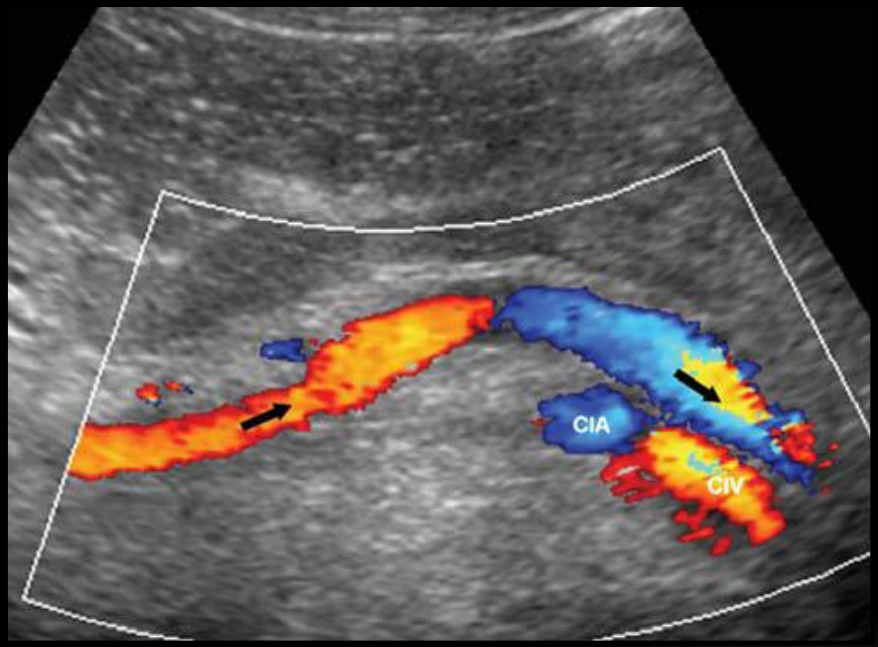

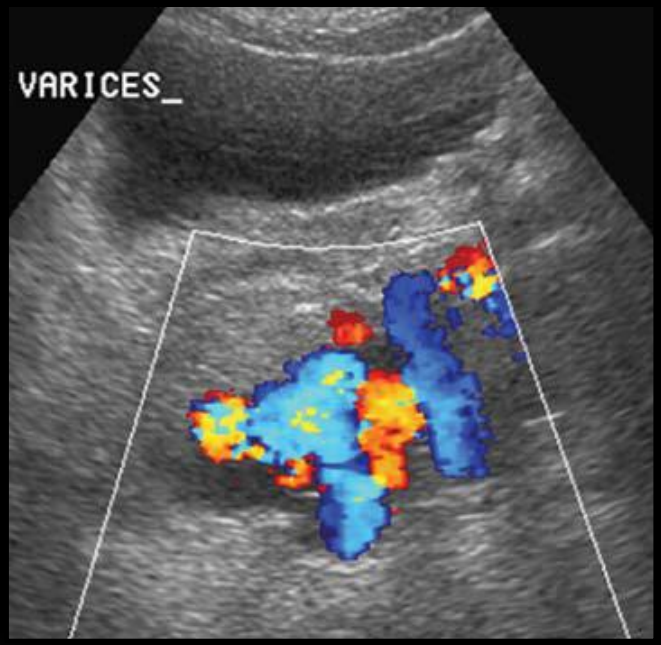

Wachsberg RH. Am J Roentgenol 2005 ; 184 : 481 – 486.

VASOS GASTROESOFÁGICOS

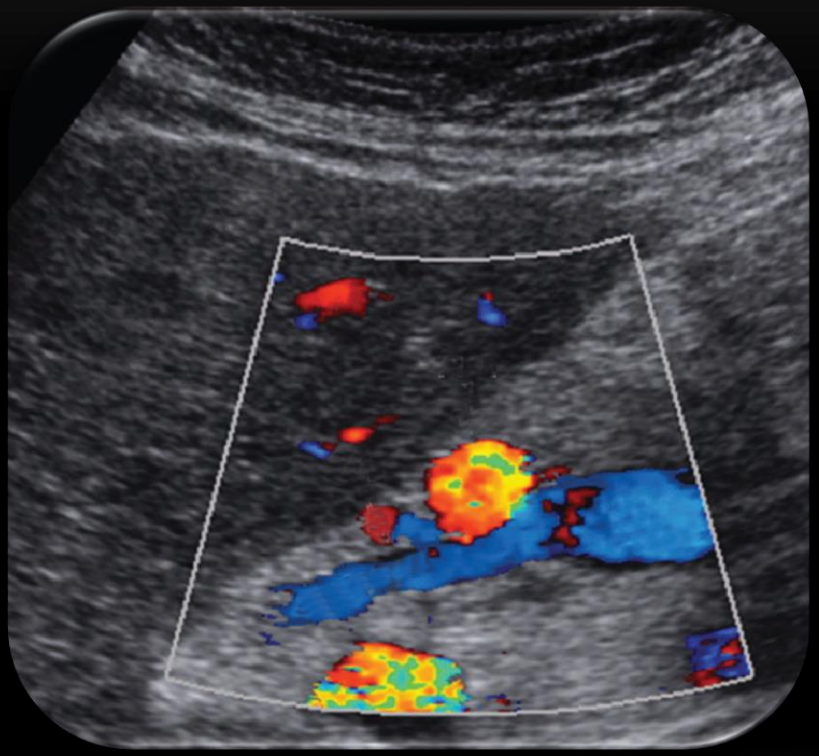

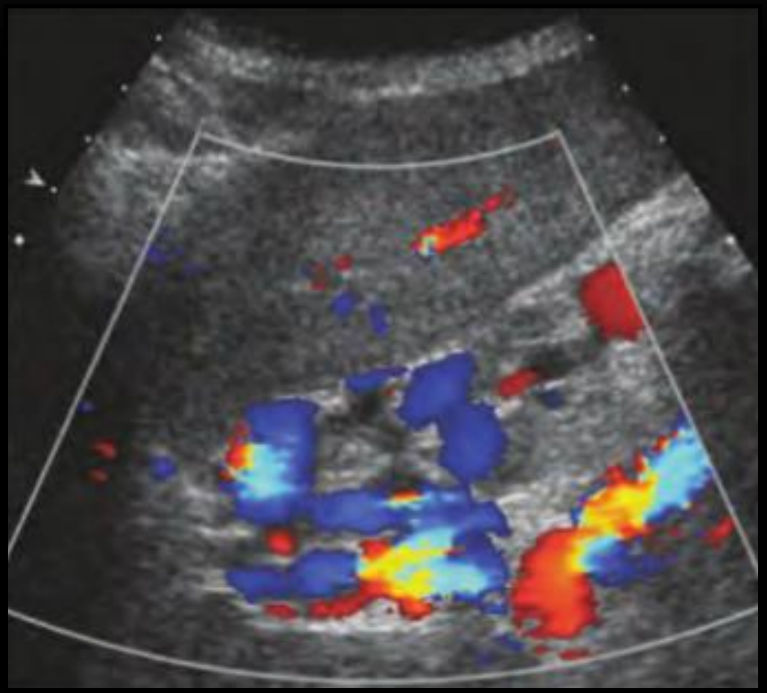

Veia gástrica esquerda (coronária)

McGahan J et al. Diagnostic ultrasound, Informa Healthcare, 2nd edition, 2008.

VARIZES ESOFÁGICAS

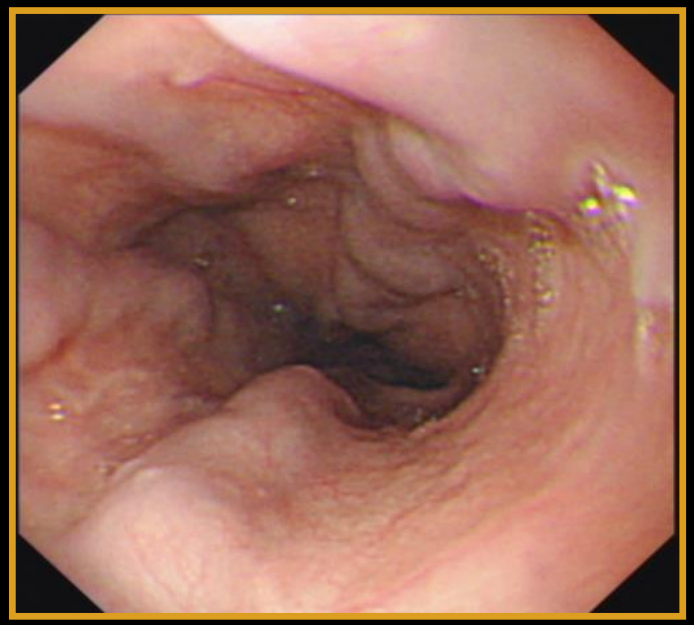

TÚLIO MACEDO - TAMACEDO@HOTMAIL.COM

VARIZES PERICOLECÍSTICAS

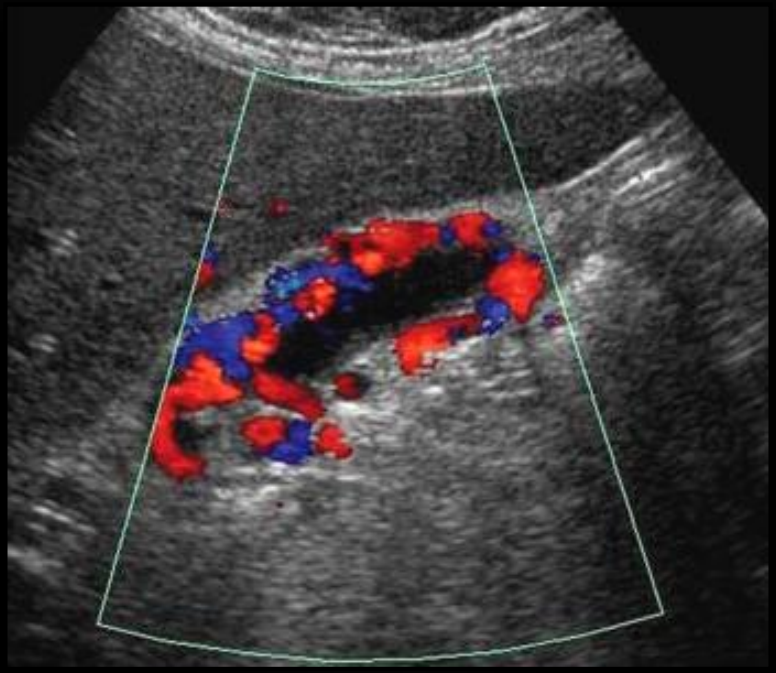

Harkanyi Z. Ultrasound Clin 2006 ; 1 : 443 – 455.

VARIZES OMENTAIS

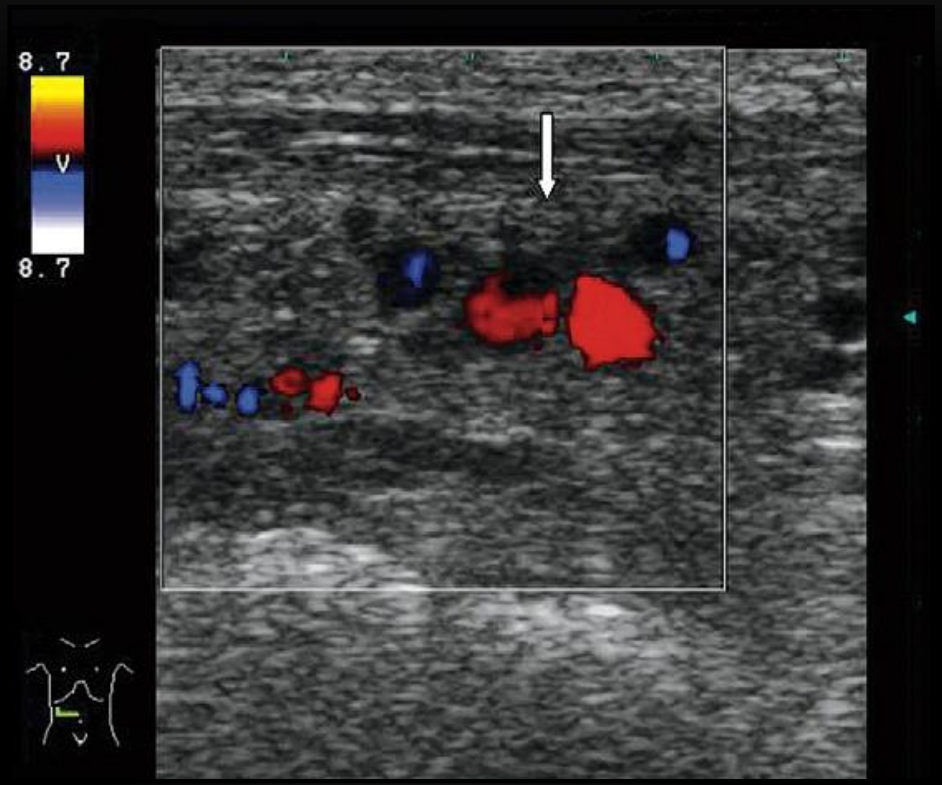

Mansour MA et al. Vascular Diagnosis. Elsevier-Saunders, Philadelphia, 1st edition, 2005

CONTATO:
TAMACEDO@HOTMAIL.COM